



## PATIENT PRESENTING CLINICAL SIGNS

Maggie Gilchrist Acute LH lameness running in snow 24 hours ago. Limb is swollen at and distal to stifle. Currently on Galliprant, Dasaquin for pre-existing DJD and Omeprazole, EN for vomiting (recent workup was NR except for elevated ALT)...Hx of prior MCT excision 5 yrs ago

## SPECIES

Canine

## COMPUTED TOMOGRAPHIC STUDY OF THE HIND LIMBS

Plain and post contrast studies are available for review.

## BREED

Labrador Retriever

## COMPUTED TOMOGRAPHIC FINDINGS

## SEX

FS

There is an ill-defined heterogeneous contrast enhancing soft tissue attenuating mass centered lateral to the left femoral tibial joint. The lesion infiltrates adjacent musculature with indistinct margins and measures ~ 6 x 3 x 3.5 cm. The surrounding musculature shows loss of fascicular architecture. Extensive subcutaneous and interfacial fluid tracks proximally and distally throughout the left hind limb compatible with marked regional inflammation, hemorrhage or cellulitis. No mineralization or gas inclusions are identified within the lesion. There is no evidence of osteolysis, periosteal reaction or cortical destruction of the adjacent femur, tibia, fibula.

## AGE

11yr

Moderate enlargement of the left popliteal lymph node is noted.

No comparable soft tissue lesions are identified in the right hind limb

A small subcutaneous 0.5 cm sized nodule medial to the left stifle was seen.

## INTERPRETED BY

Nele Eley (Ondreka),  
DVM Dr. med. vet.,  
DipECVDI

## COMPUTED TOMOGRAPHIC DIAGNOSIS

- Infiltrative tissue lesion lateral to the left stifle with heterogeneous enhancement and muscular involvement.
- Extensive regional subcutaneous and fascial fluid accumulation throughout the left hind limb
- Moderate left popliteal lymphadenomegaly
- Small subcutaneous soft tissue nodule medial to left stifle

## HOSPITAL NAME

Animal Clinic  
Northview

## INTERPRETATION OF FINDINGS & FURTHER RECOMMENDATIONS

## REFERRING VET

Steven Cudia DVM

The imaging appearance suggests an aggressive soft tissue process without current bone involvement. Soft tissue neoplasia such as sarcoma is a primary differential diagnosis. Post traumatic organizing hematoma, inflammatory / infectious processes, mast cell tumor recurrence or metastasis is considered less likely but cannot be ruled out entirely.

## INVOICE

23872

The popliteal lymph node enlargement may be reactive, however potential metastatic disease cannot be ruled out. Given the acute clinical onset, traumatic hemorrhage with organizing hematoma and secondary inflammation remains a differential. However, the degree of soft tissue infiltration warrants definitive characterization to rule out neoplasia. FNA or core biopsy of the lesion is recommended for further definition as well as FNA of the left popliteal lymph node.

## DATE

02/12/2026



## PATIENT

Maggie Gilchrist

## SPECIES

Canine

## BREED

Labrador Retriever

## SEX

FS

## AGE

11yr

## INTERPRETED BY

Nele Eley (Ondreka),  
DVM Dr. med. vet.,  
DipECVDI

## HOSPITAL NAME

Animal Clinic  
Northview

## REFERRING VET

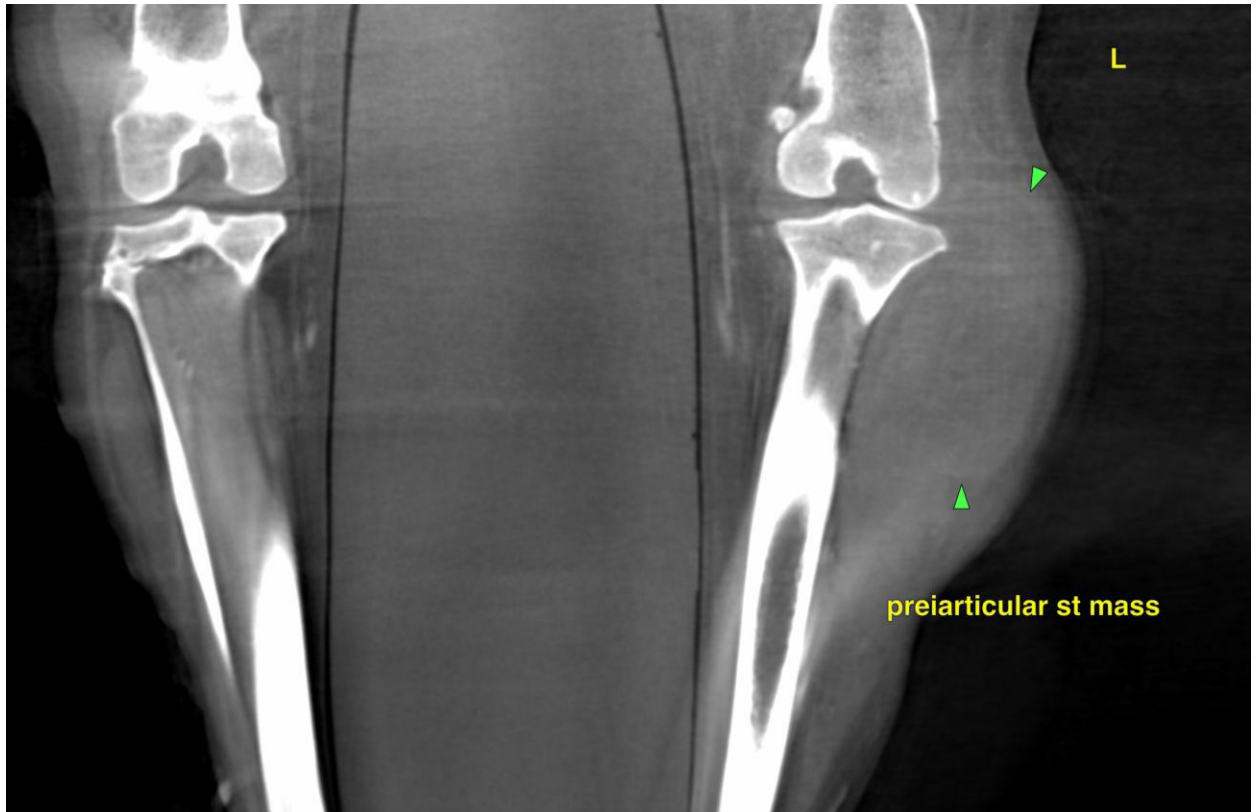
Steven Cudia DVM

## INVOICE

23872

## DATE

02/12/2026





## PATIENT

Maggie Gilchrist

The information and recommendations provided are based on the images presented by the referring veterinarian. No evaluation can be communicated regarding pathology that was not visible in the image/video clips provided.

## SPECIES

Canine

Thank you for this referral. If the clinical or image interpretation does not parallel your findings or if I can be of any further assistance please contact me.

## BREED

Labrador Retriever

Nele Eley (Ondreka), DVM, Dr. med. vet., DipECVDI  
European Specialist in Veterinary Diagnostic Imaging, Cert. Radiology,  
Senior lecturer University of Giessen/Germany, Veterinary Faculty, Department of Radiology.  
[info@sonopath.com](mailto:info@sonopath.com)

## SEX

FS

## AGE

11yr

## INTERPRETED BY

Nele Eley (Ondreka),  
DVM Dr. med. vet.,  
DipECVDI

## HOSPITAL NAME

Animal Clinic  
Northview

## REFERRING VET

Steven Cudia DVM

## INVOICE

23872

## DATE

02/12/2026